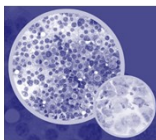

Introdução à citologia. Pontos críticos na obtenção envio e processamento de amostras

Ricardo Marcos

Patologia Clínica
Workshop de Citologia

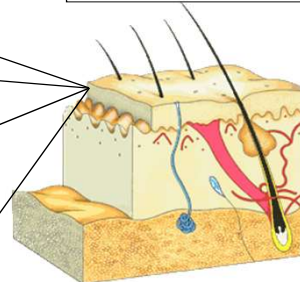
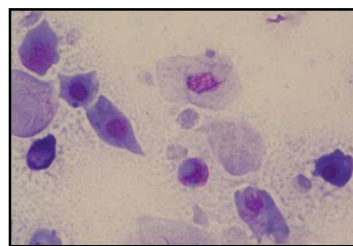


Introdução à citologia

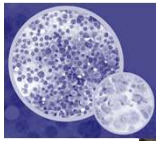
→ Objectivo: emissão de um diagnóstico...

Citologia

Histopatologia



→ Limitações e vantagens da citologia



Diagnóstico: Citologia vs Histopatologia

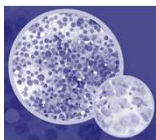


Citologia

"Inductive reasoning"

Histopatologia

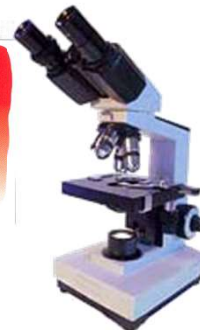
"Pattern recognition"

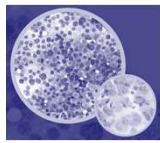


Recolha do material: Cito. vs Histopatologia

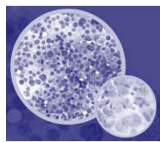
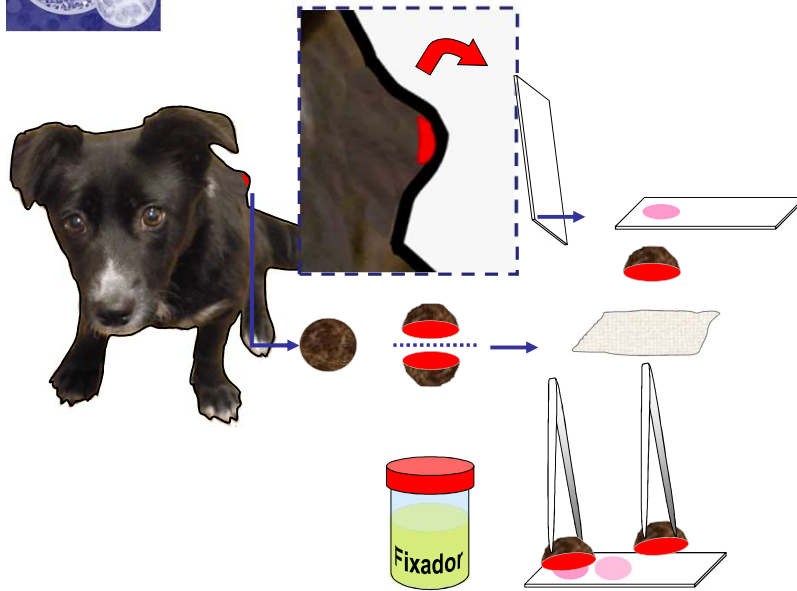


Impressão
Raspagem
Zaragatoa
Punção de
agulha fina

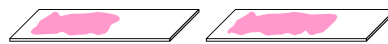
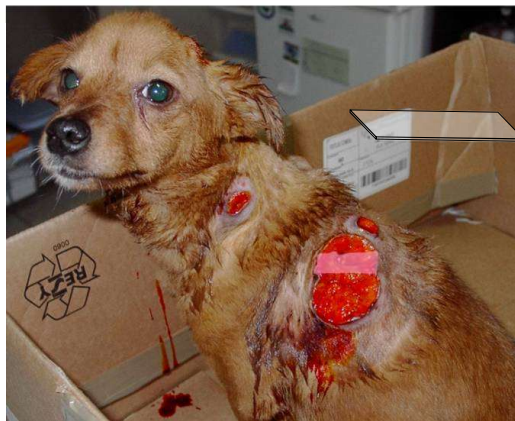

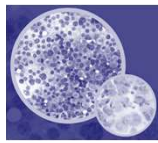


Impressão

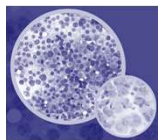
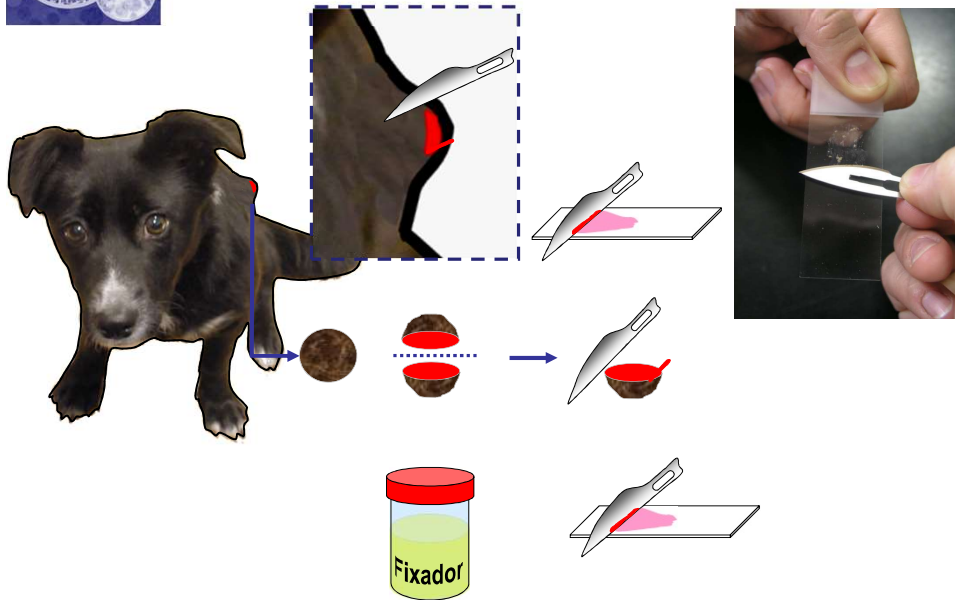


Impressão

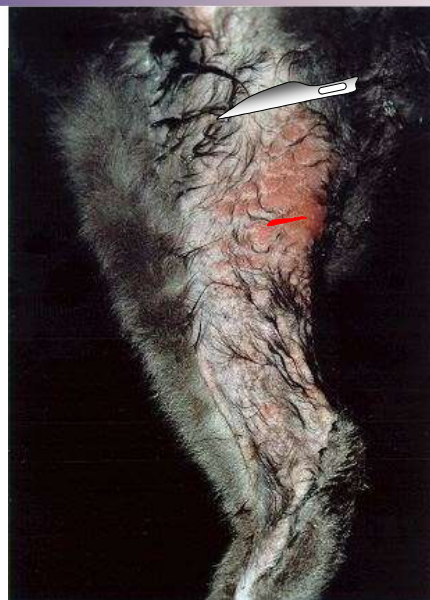


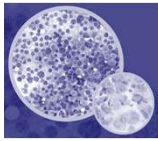


Raspagem

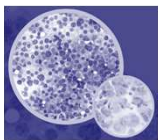
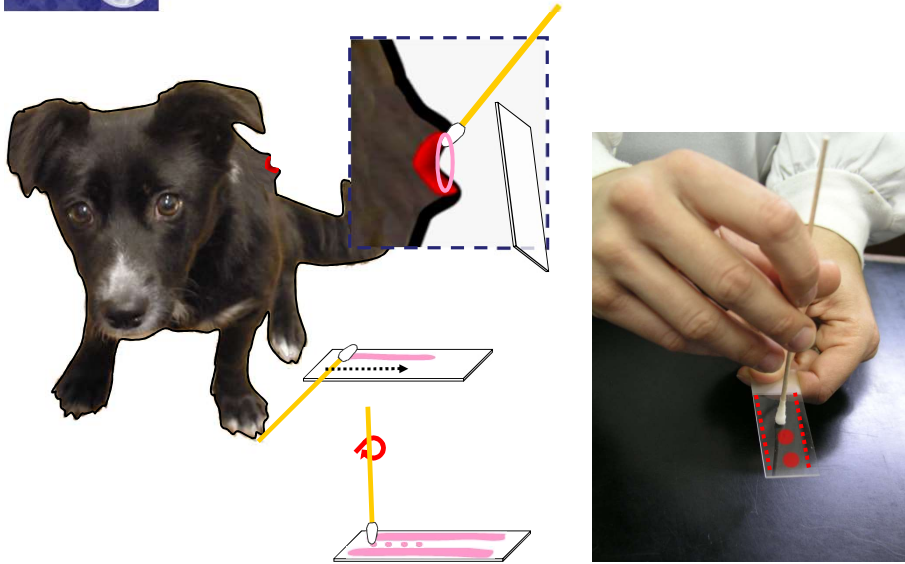


Raspagem

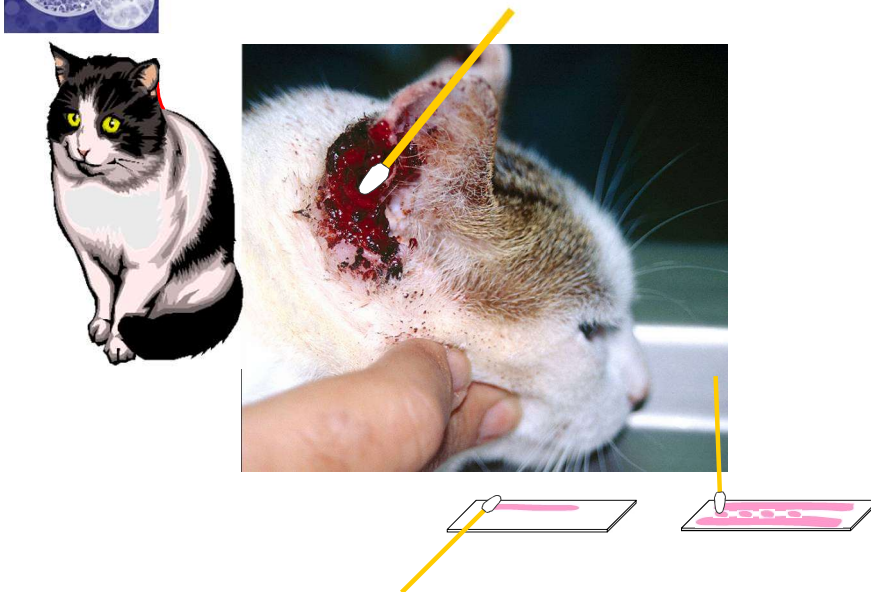


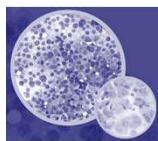


Zaragatoa

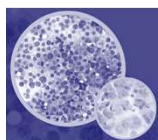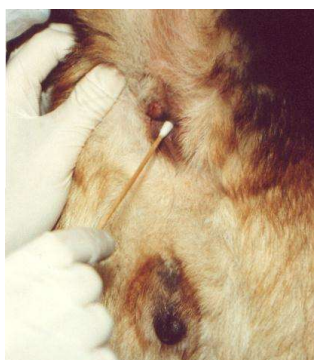

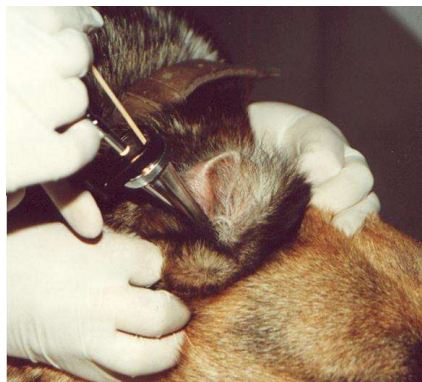
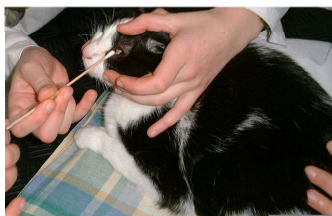Zaragatoa

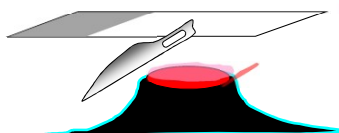




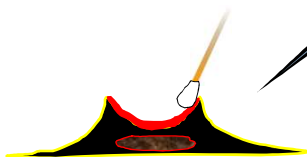
Zaragatoa



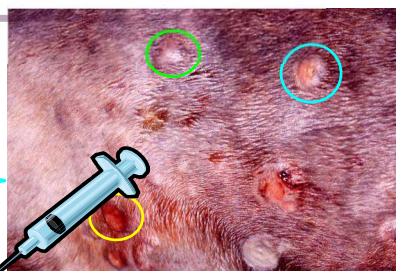
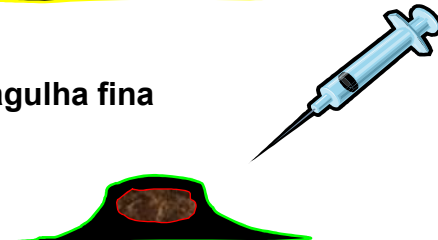
**Impressão
Raspagem**

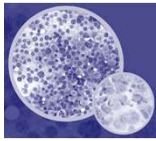


Zaragatoa

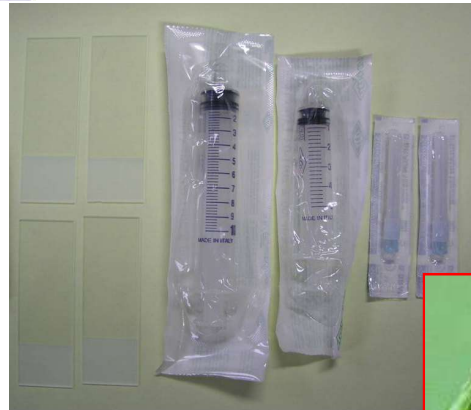

Punção com agulha fina





Punção de agulha fina: material?

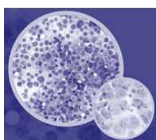


↪ seringa de 10ml com agulha 23G



21G

25G



Punção de agulha fina (PAF): material

Prospective study to investigate the use of fine needle aspiration techniques in UK veterinary practice

K. L. BOWLE, R. NEWTON*, S. MURPHY†, L. BLACKWOOD‡ AND M. STARKEY§
Journal of Small Animal Practice (2014) **55**, 409–414

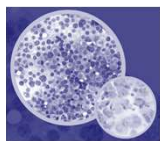170 questionários UK++, Europa, USA

66,5 % PAAF; 43,5% PNAAF

Seringa e diâmetro de agulha sem interferência (≠ humana)

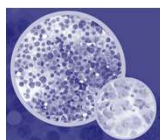
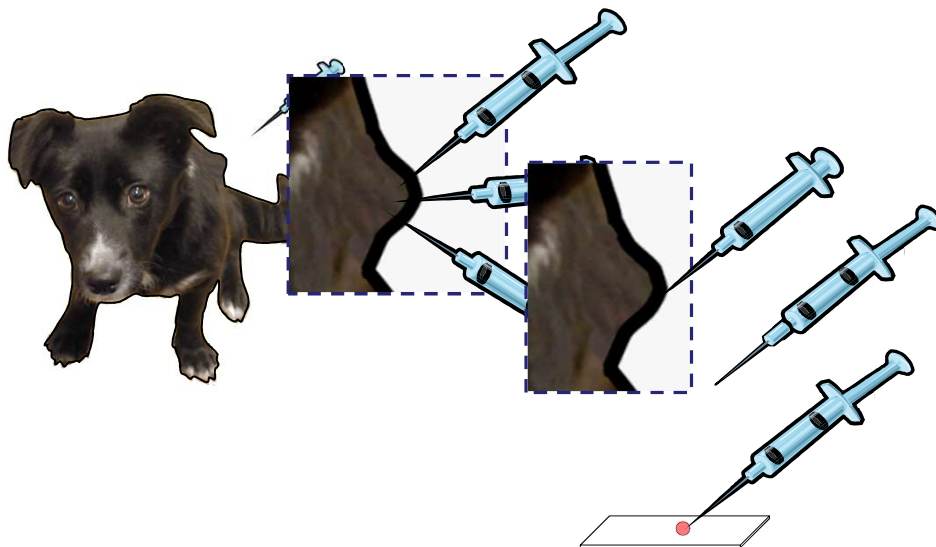
Table 3. Number (%) of respondents routinely using combination of different sized needles and syringes

Needle used (gauge)	Syringe used					
	1 mL	2 mL	5 mL	10 mL	20 mL	50 mL
25 G	0	4 (3.4)	2 (1.2)	0	0	0
23 G	2 (1.2)	35 (20.6)	30 (17.6)	1 (0.6)	0	0
21 G	1 (0.6)	40 (23.5)	46 (27.1)	5 (2.9)	0	0
20 G	0	1 (0.6)	1 (0.6)	0	0	0
19 G	0	1 (0.6)	0	1 (0.6)	0	0



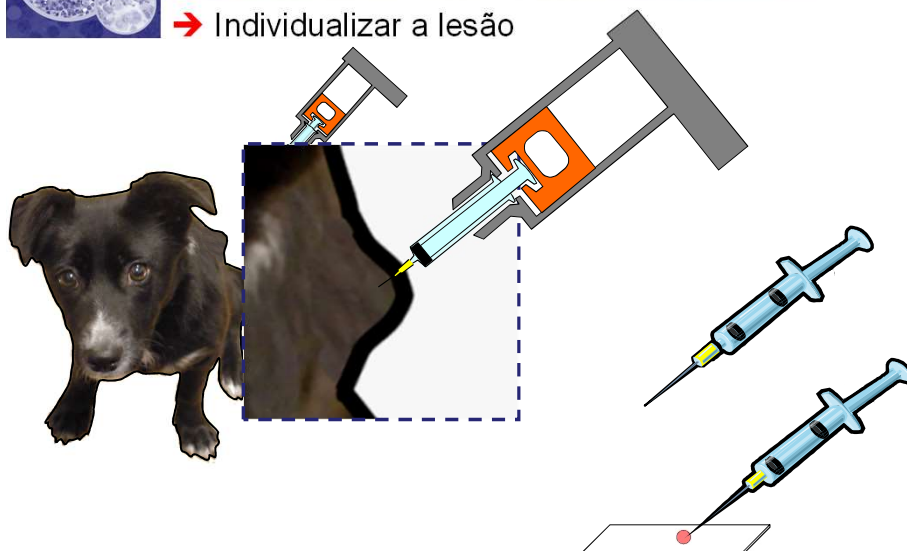
PAF: técnica aspirativa (PAAF)

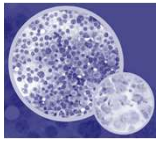
→ Individualizar a lesão



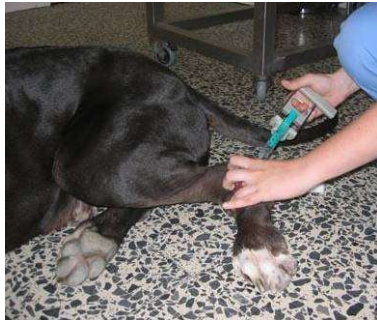PAF: técnica aspirativa (punho)

→ Individualizar a lesão

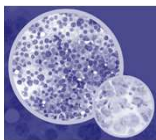
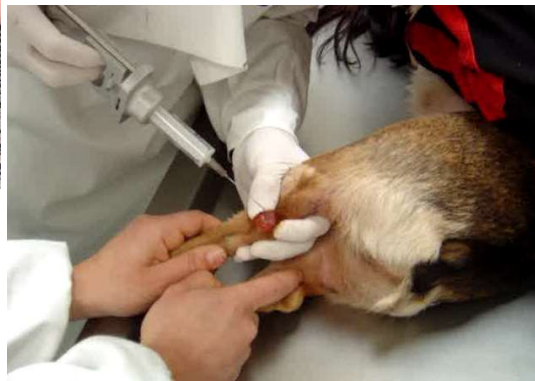



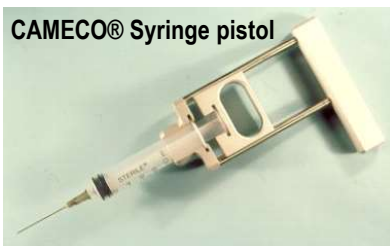Punho de aspiração



→ Vantagens e desvantagens




Punhos de aspiração



CAMECO® Syringe pistol



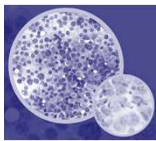
INRAD® Aspiration Biopsy syringe gun




Jrovet® Aspir-gun



Torneiro® Versão *home-made*



Punhos de aspiração

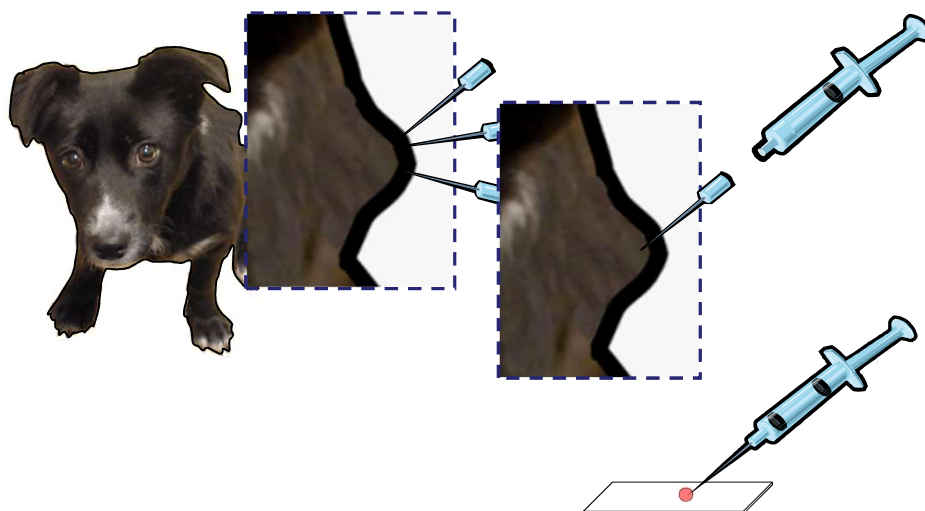


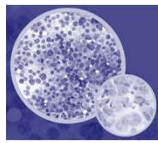
Versão 3D home-made



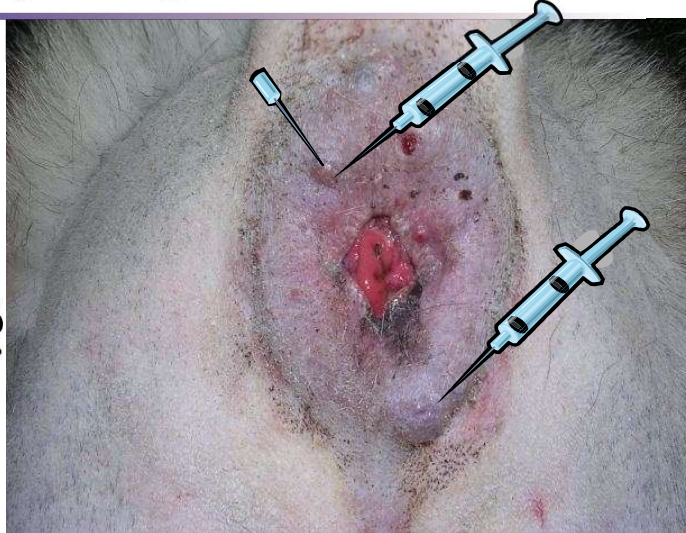
Punção agulha fina: técnica não-aspirativa

→ Individualizar a lesão

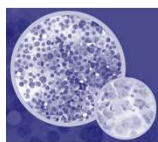



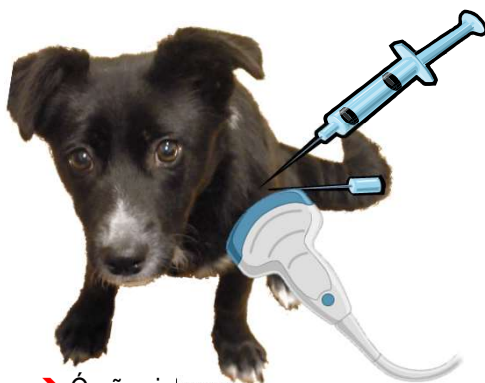Punção de agulha fina



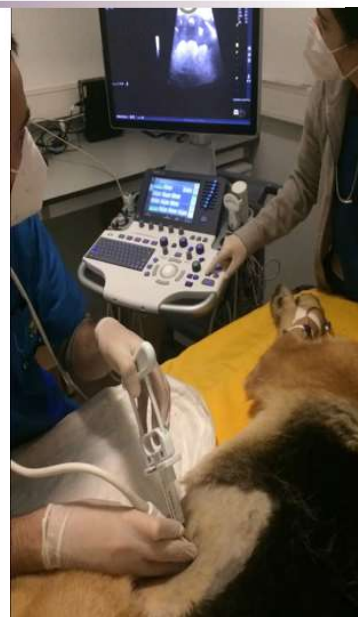
→ Vantagens e desvantagens

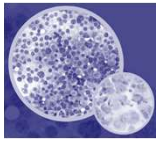


Punção de agulha fina

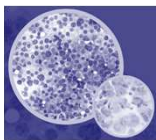
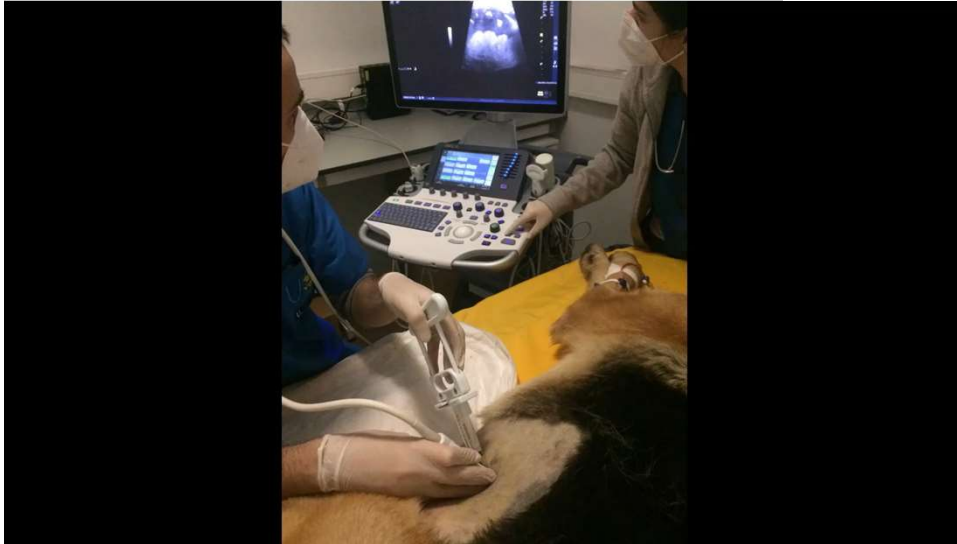

- Órgãos internos
- Preparação cirúrgica da área


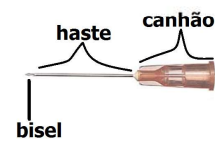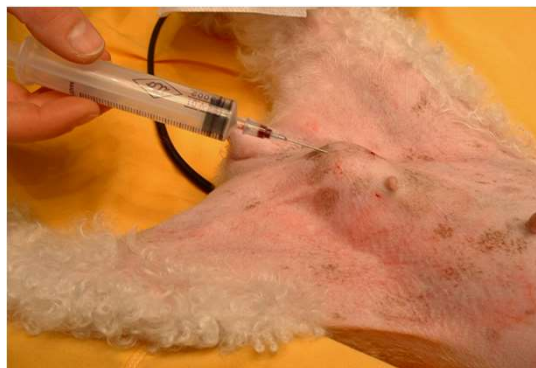




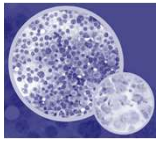
Punção de agulha fina



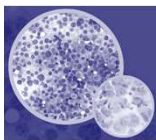
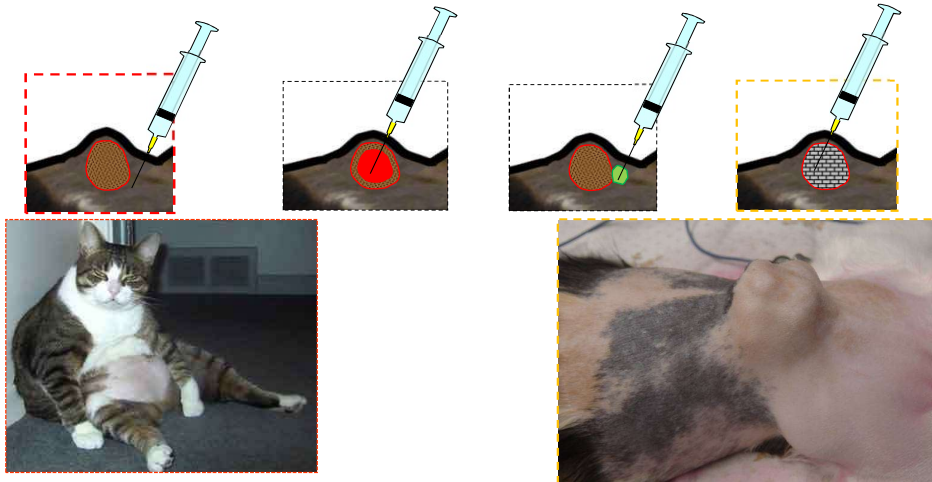
Maus resultados na PAAF (1)



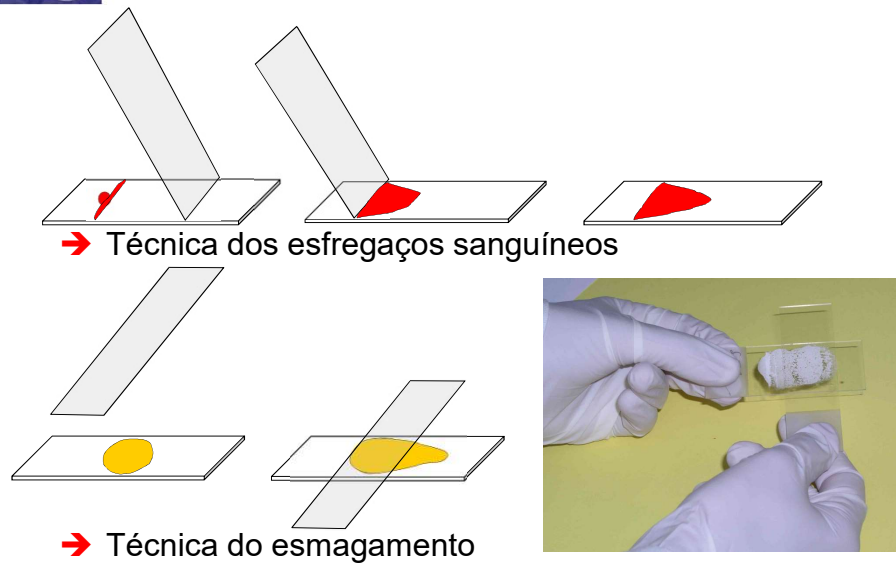
- Parar quando há hemorragia ou material entra para seringa
- Lesões quísticas subcutâneas → Centrifugação do líquido

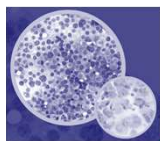


Maus resultados na PAAF (2)



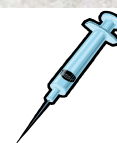
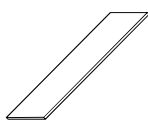
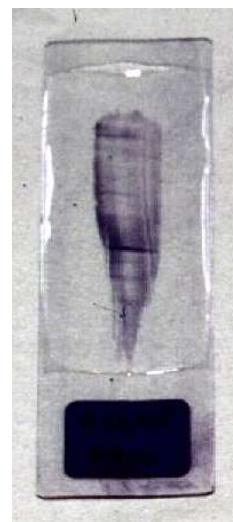
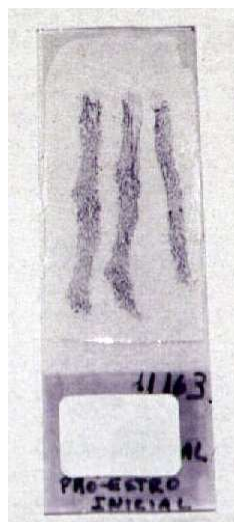
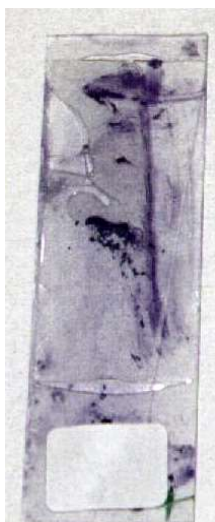
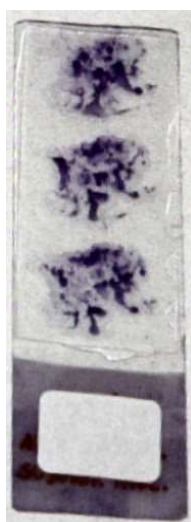
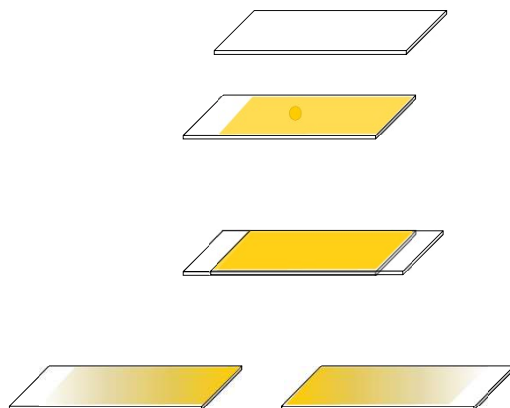
Extensão do material na lâmina

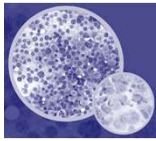




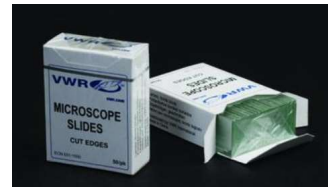
Técnica de "squash"

→ Amostras tipo muco ou líquidas



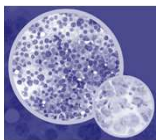


Ainda sobre o material: lâminas

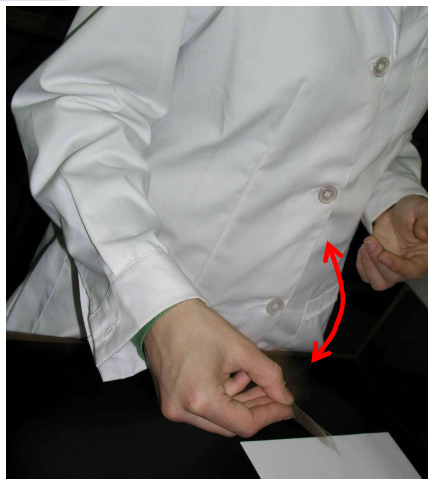

Fosco 3,40€ vs lisas 2,90€

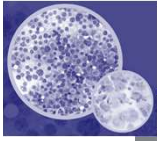
→ Limpas; evitar reutilização



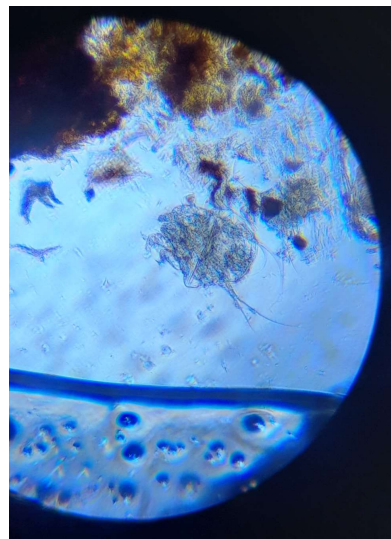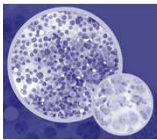
Depois de obter os esfregaços...

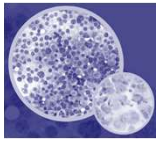


→ Secagem → Coloração



- Avaliação do material → coloração; **fixação húmida?**
- Proteger do pó; **não refrigerar**

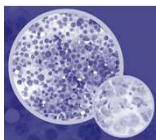




Coloração Diff-Quik



Fixador **Vermelho** **Azul**




Fixador

→ Evapora ⇨ fechar bem o frasco

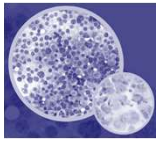


→ pt.vwr.com: 34,1€
(13,6 €/L)






→ pt.vwr.com (Merck):
6,78 €/L

→ www.enzymatic.pt
(VR0260): 1,31 €/L

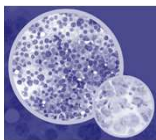


Estado dos corantes - filtrar

→ Periodicamente; nomear responsável




→ Substituição dos corantes



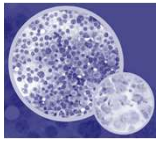
Técnica de coloração (1)

→ Variável ⇨ importante uniformizar; familiarizar




→ 1+2+3 min.

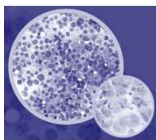
→ 10+15+20 mergulhos



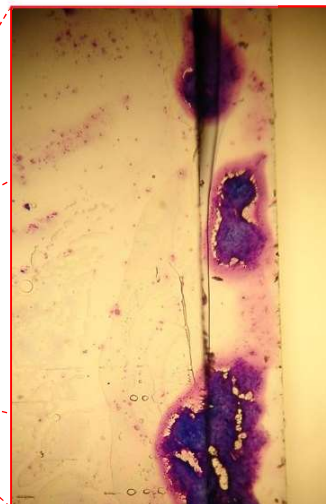
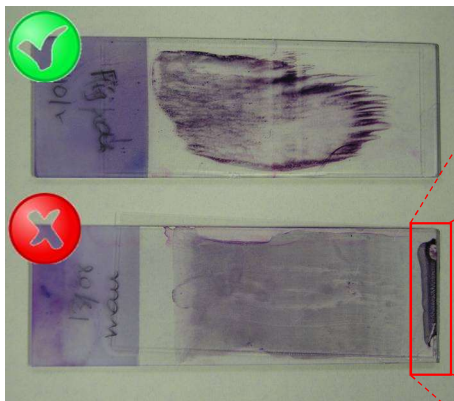
Técnica de coloração (2)

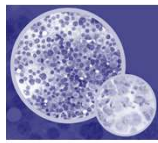


→ estufa ou secador

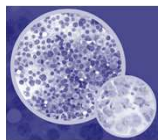
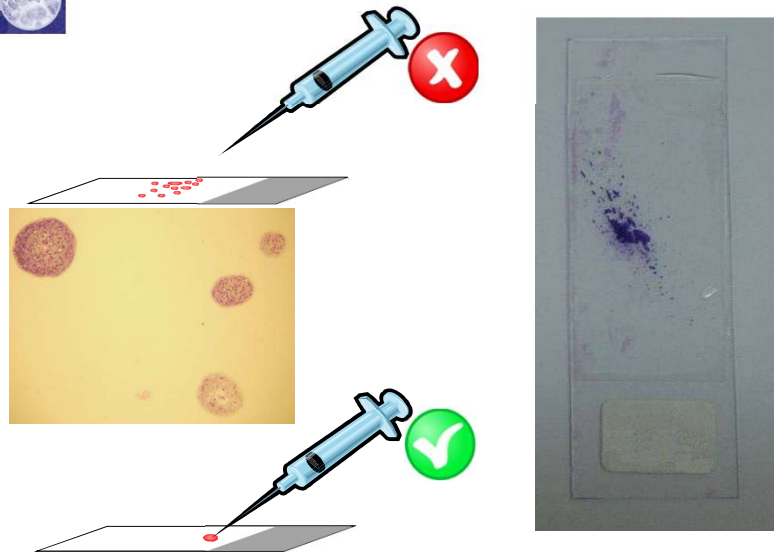


Maus exemplos (1)

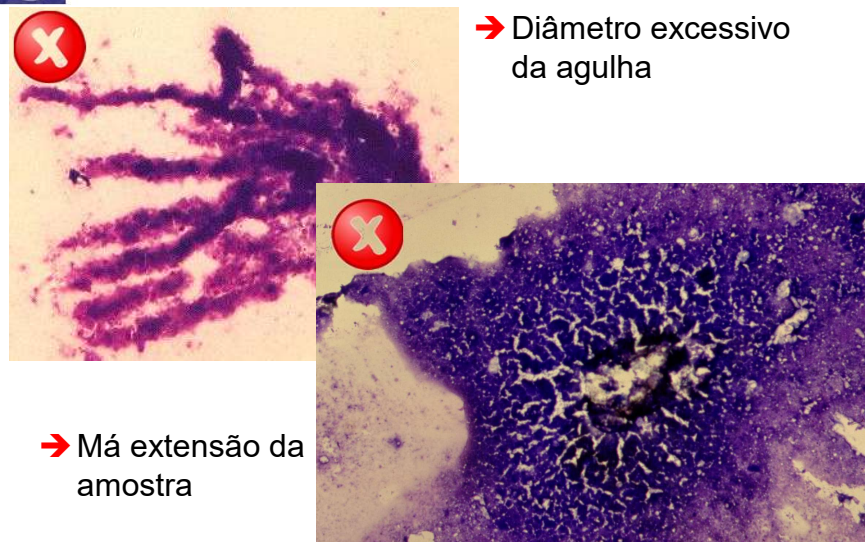

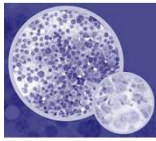


Maus exemplos (2)



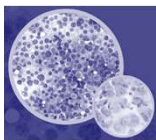
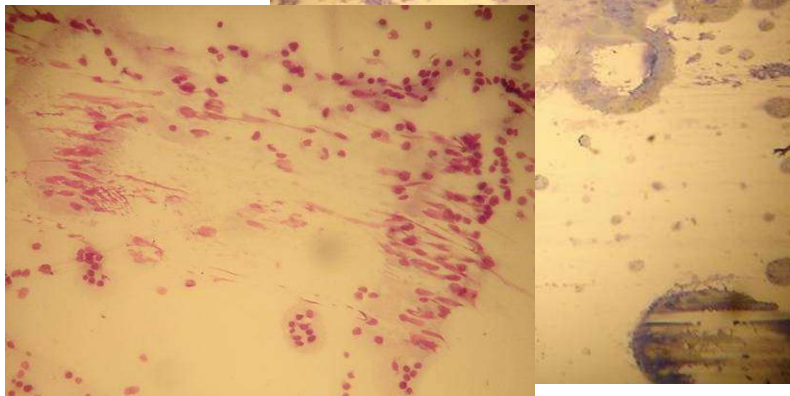
Maus exemplos (3)



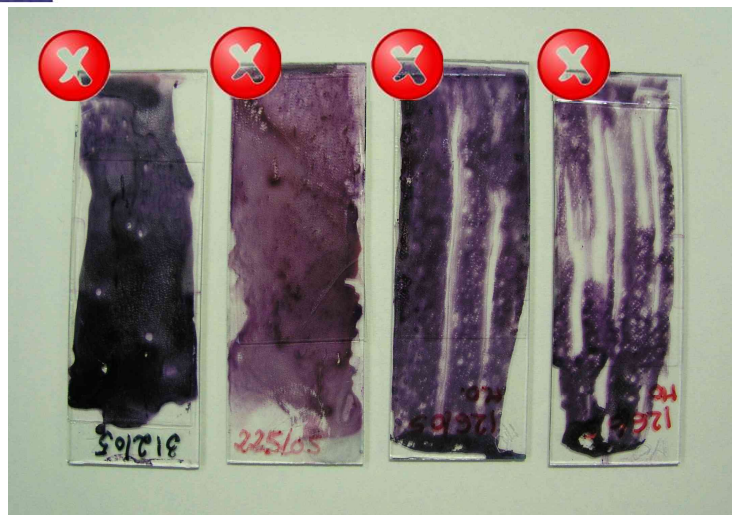


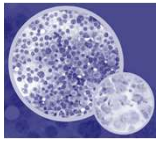
Maus exemplos (4)

→ Força excessiva no esfregão

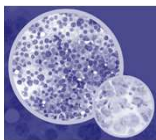
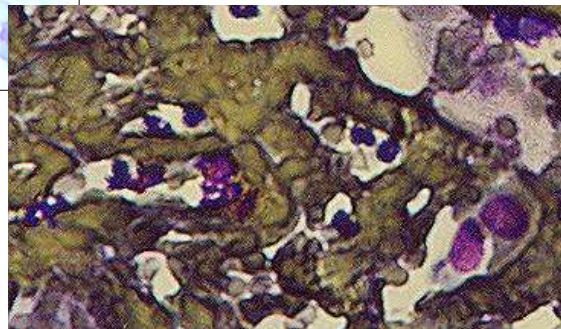
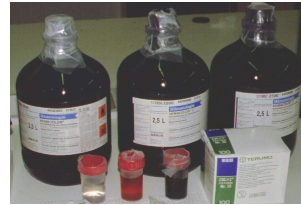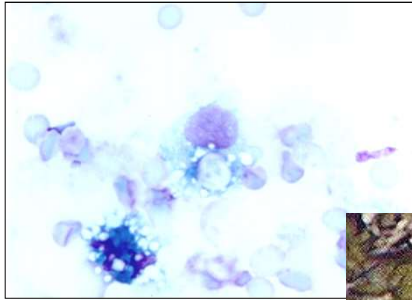


Maus exemplos (5)

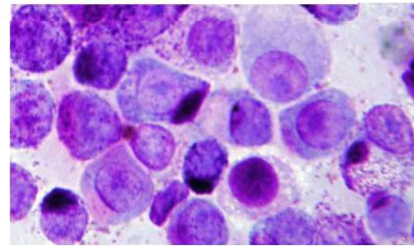




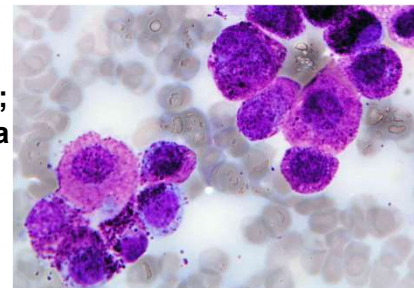
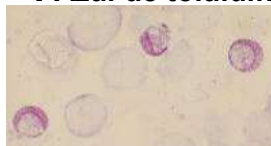Avaliação da coloração

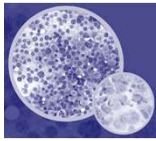


Coloração de mastócitos



- mínimo 30seg. fixador?
- dúvidas → May-Grunwald;
→Azul de toluidina





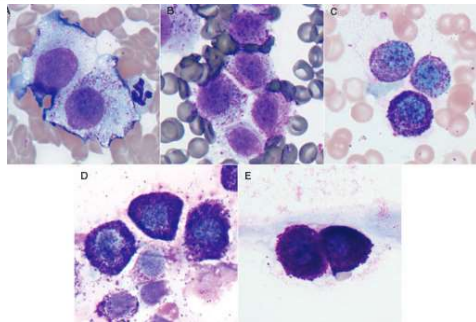
Coloração de mastócitos

BRIEF COMMUNICATION *Vet Clin Pathol* 42/1 (2013) 99–102 ©2012 American Society for Veterinary Clinical Pathology

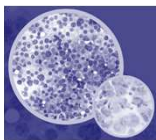
Evaluation of fixation time using Diff-Quik for staining of canine mast cell tumor aspirates

Dorothy E. Jackson¹, Kim A. Selting¹, Melanie S. Spoor², Carolyn J. Henry^{1,3}, Charles E. Wiedmeyer²

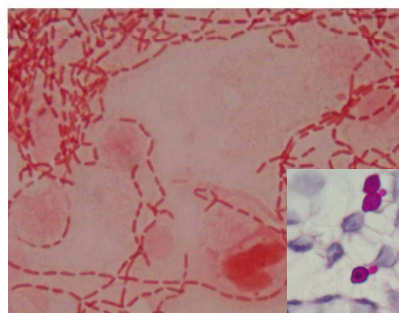
- 21 casos
- Fixação: 5 seg. a 2 min.
- Avaliação qualitativa e análise de imagem



- Não havia diferenças entre grupos
- Alguns mastocitomas podem necessitar de colorações especiais

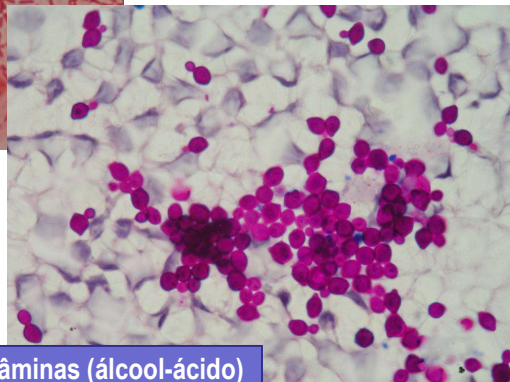


Outras colorações em citologia (1)

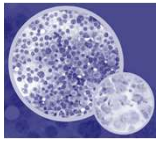


↪ coloração de Gram
→ antibioterapia

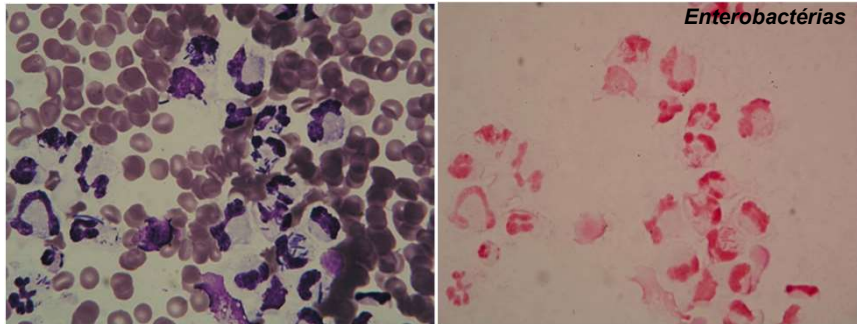
↪ coloração PAS →
parede fungos e
adenocarcinoma



Possível → decorar lâminas (álcool-ácido)
ou corar por cima do Diff-Quik



Técnicas histoquímicas auxiliares (2)



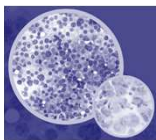
➔ **Coloração de Gram para bactérias**

Vet Clin Pathol 38:1 (2009) 94-102 © 2009 American Society for Veterinary Clinical Pathology

Use of destained cytology slides for the application of routine special stains

R. Marcos, M. Santos, N. Santos, F. Malhão, F. Ferreira, R.A.F. Monteiro, E. Rocha

Cytology Diagnostic Services, Laboratory of Histology and Embryology, ICBAS - Institute of Biomedical Sciences Abel Salazar, U2, University of Porto, Porto, Portugal



Técnicas de imunocitoquímica (3)

CD3 unstained

CD3 retained

↳ **CD3, CD20, HLA-II, lisozima, MUM-1, Melan-A, vimentina, citoqueratinas**

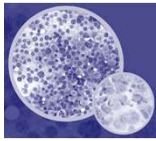
TECHNICAL REPORT

MARKER	DILUTION	TOTAL REAGENT	I/P AB	DILUENT
CD3				
CD20				
HLA2				

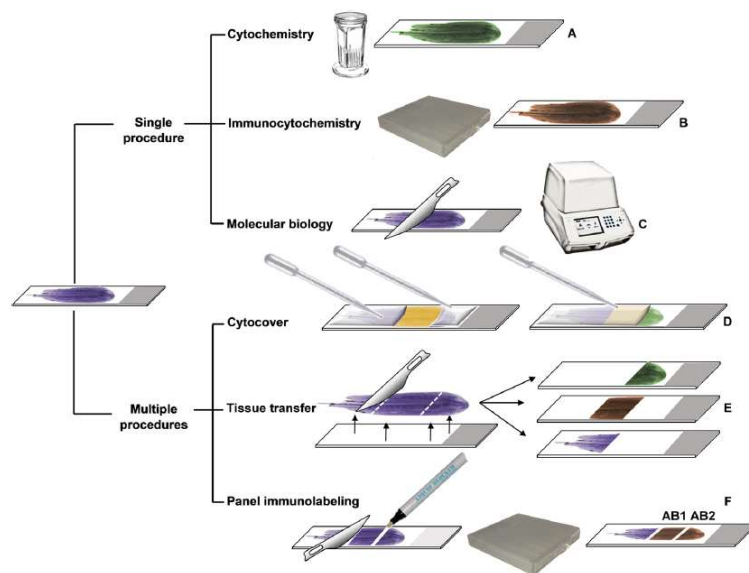
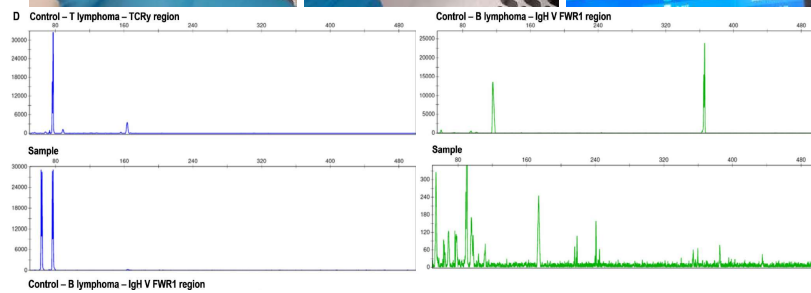
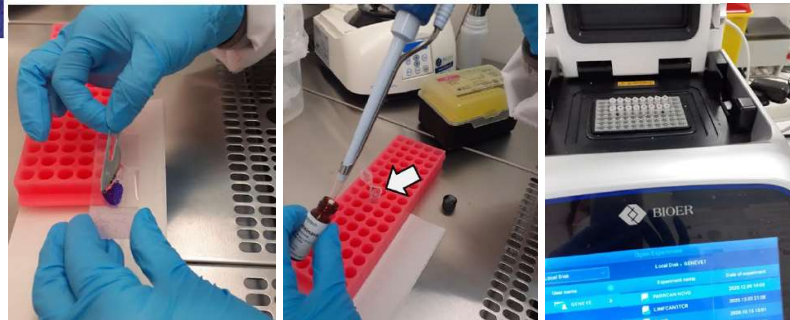
Optimized immunocytochemistry using leukocyte and tissue markers on Romanowsky-stained slides from dogs and cats

Rose E. Raskin¹ | Julie Vickers² | Jennifer G. Ward³ | Angus Toland³ | Andrew G. Torrance²

Veterinary Clinical Pathology
An International Journal of Laboratory Medicine
WILEY

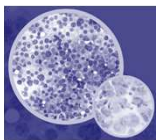


Técnicas de biologia molecular (4)

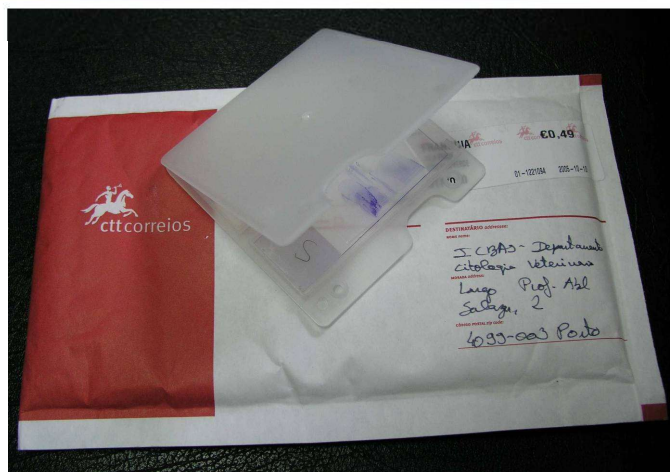

Doing more with less: multiple uses of a single slide in veterinary cytology. A practical approach

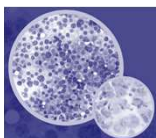
Carla Marrinhas^{1,2} · Fernanda Malhão² · Célia Lopes² · Filipe Sampaio^{2,3} · Raquel Moreira^{2,4} · Mario Caniatti⁵ · Marta Santos² · Ricardo Marcos²



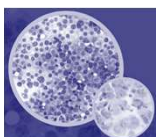
Envio de amostras para o laboratório (1)



- ➔ **Lâminas coradas (opcional) + por corar**
- ➔ **Ficha de requisição...preenchida!**

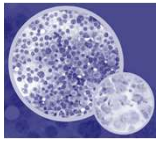


Envio de amostras para o laboratório (2)

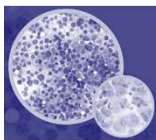


Envio de amostras para o laboratório (3)



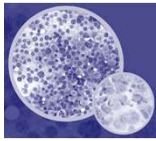


Envio de amostras para o laboratório (4)

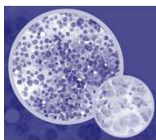
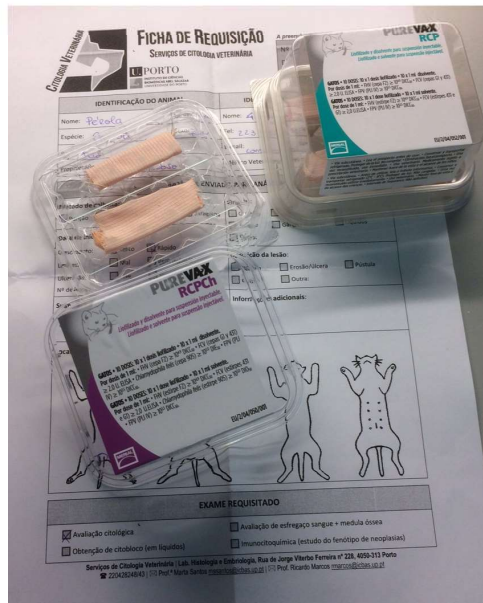


Envio de amostras para o laboratório (5)





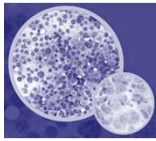


Envio de amostras para o laboratório (6)

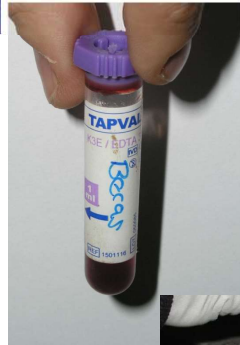

Envio de amostras para o laboratório (5)





Envio de líquidos(1)



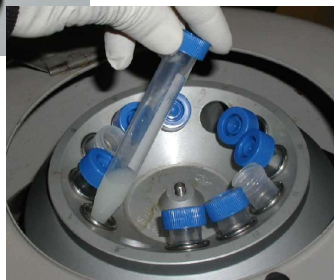→ Frasco com EDTA
(anticoagulante+inibe fagocitose)

+

→ Esfregaço direto

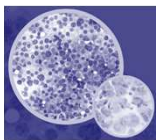
↳ turvos a opacos → esf. direto

↳ translúcidos → esfregaço em linha



→ Centrifugação
(1500rpm-5min)

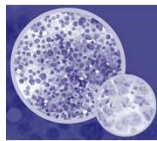
↳ ressuspender!



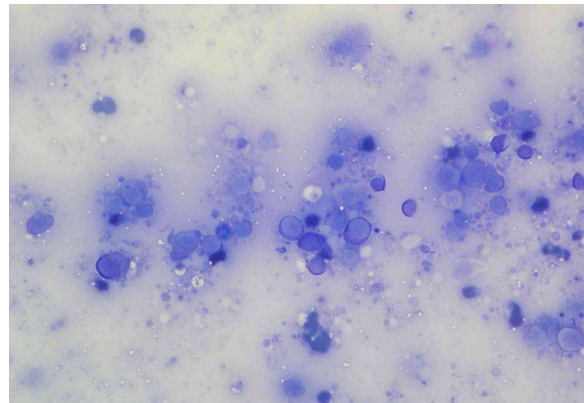

Processamento de líquidos no laboratório



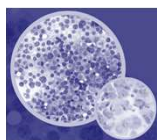↳ citospin → esfregaço em monocamada!



Formol e a citologia...!!



⚠ cuidado no processamento e envio de amostras!



Utilização diagnóstica da Citologia (1)

Factors affecting the diagnostic utility of canine and feline cytological samples

R. SAPIERZYŃSKI^{*1}, M. CZOPOWICZ[†] AND M. OSTRZESZEWICZ[‡]

Journal of Small Animal Practice (2017) **58**, 73–78

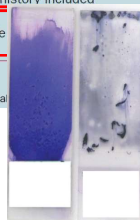
Table 2. Univariable analysis of relationships between potential categorical

N	Potential predictor of obtaining definitive cytological result	Category
1.	Species	Dog Cat
2.	Location of the lesion [†]	Superficial Deep
3.	Data included in the cover letter ^{†,‡}	Only basic Description of the lesion included Medical history included
4.	Macroscopic appearance of slides [‡]	Poor Moderate Good

^{*}Result statistically significant at the significance level of 0.05

[†]Categorical variables included in the multiple logistic regression model (P<0.2)

[‡]Categorical variables included in the multiple logistic regression model as dummy varia



FICHA DE REQUISIÇÃO
SERVIÇOS DE CITOLOGIA VETERINÁRIA

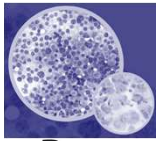
PORTO
CENTRO VETERINÁRIO

A preencher internamente

Nº da análise: _____
Data de receção: _____
Material enviado: _____

IDENTIFICAÇÃO DO ANIMAL	IDENTIFICAÇÃO HOSPITAL/CLÍNICA
Nome: _____	Nome: _____
Espécie: _____	Sexo: _____
Raça: _____	Tel: _____
Proprietário: _____	E-mail: _____
	Médico Veterinário: _____
MATERIAL ENVIADO PARA ANÁLISE	
Método de coleta: <input type="checkbox"/> punção <input type="checkbox"/> raspagem <input type="checkbox"/> impressão <input type="checkbox"/> coragem	Origem: <input type="checkbox"/> cutânea <input type="checkbox"/> vaginal <input type="checkbox"/> medula óssea <input type="checkbox"/> sangue <input type="checkbox"/> esôfago linfático <input type="checkbox"/> líquido
Data de início: _____	<input type="checkbox"/> outra
Crescimento: <input type="checkbox"/> lento <input type="checkbox"/> rápido	Descrição da lesão: <input type="checkbox"/> nódulo <input type="checkbox"/> erosão/úlceras <input type="checkbox"/> pústula
Limite: <input type="checkbox"/> mal <input type="checkbox"/> bem definido	<input type="checkbox"/> líquido <input type="checkbox"/> outro
Localização: <input type="checkbox"/> raso <input type="checkbox"/> em	Suspeita clínica: _____
Informações adicionais: _____	
EXAME REQUISIADO	
<input type="checkbox"/> citológica <input type="checkbox"/> avaliação de esfregaço sangue + medula óssea <input type="checkbox"/> não citológica (sem líquido) <input type="checkbox"/> imunocitoquímica (exclusão de neoplasias)	

Rua de Clotilde Veterinária, Lda, Histologia e Citologia, Rua de Jorge Vilhano Pereira nº 228, 4800-313 Porto
 Tel: 226282644 | Prof. Ricardo Santos rsantos@porto.vet.pt | Prof. Ricardo Amorim ramorim@porto.vet.pt



Utilização diagnóstica da Citologia (2)

Prospective study to investigate the use of fine needle aspiration techniques in UK veterinary practice

- 170 questionários
- 48% avaliação externa; 42% mista (avaliação prévia); 10% avaliação interna

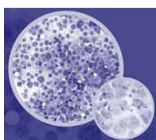
K. L. BOWLE, R. NEWTON*, S. MURPHY†, L. BLACKWOOD‡ AND M. STARKEY§

Journal of Small Animal Practice (2014) **55**, 409–414
DOI: 10.1111/jsap.12234

Table 2. Responses to the question "If you elect to proceed with an investigation, how often do you perform FNA initially?"

Question: If you elect to proceed with investigation, how often do you perform FNA in the first instance?	Number of respondents (%)	Years since graduation [Median (range)]	Median number of full-time vets employed (range)	Median total number of new cases seen per month (range)	Median number of new oncological cases seen per month (range)	Number of respondents with one or more postgraduate qualification (%)
Always (10 times out of 10)	36 (21-2)	10 (5 to 20)	4 (2 to 8)	100 (40 to 187)	10 (5 to 20)	9
Usually (7 to 9 times out of 10)	86 (50-6)	10 (4 to 19)	4 (3 to 6)	100 (60 to 200)	8 (5 to 15)	15
Around half the time (4 to 6 times out of 10)	31 (18-2)	16 (8 to 25)	3 (2 to 7)	100 (50 to 138)	7 (4 to 13)	5
Occasionally (2 to 3 times out of 10)	12 (7-1)	23 (11 to 30)	4 (3 to 10)	75 (40 to 100)	5 (5 to 16)	2
Rarely (0 to 1 times out of 10)	5 (2-9)	24 (7 to 39)	4 (2 to 12)	50 (3 to 100)	3 (2 to 5)	0
P-value (linear regression)		0-0002	0-98	0-15	0-019	0-15

FNA Fine needle aspiration



Utilização diagnóstica da Citologia (3)

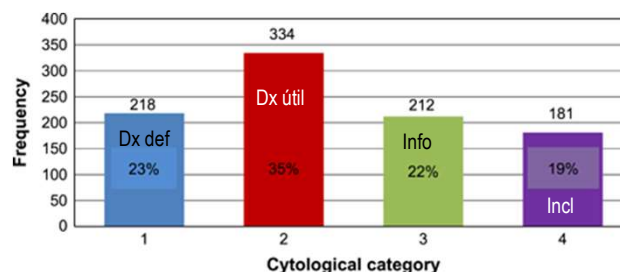
The perceived and actual diagnostic utility of veterinary cytological samples

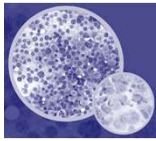
N. SKELDON AND E. DEWHURST

Journal of Small Animal Practice (2009) **50**, 180–185

- 1206 amostras (700 C, 140G, 6 cavalos, 6 exóticos); 1 de 4 citologistas
- 74 questionários a Vets/ Reino Unido

- média de amostras/semana: 3,9
- "obtenção de Dx"; "excluir/incluir Dxs"; "direcionar tratamento e testes Dx adicionais"; "teste de screening"; "detecção metástases"



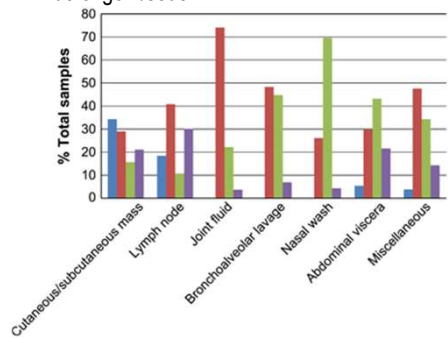


Utilização diagnóstica da Citologia (3)

N. SKELDON AND E. DEWHURST

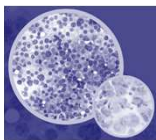
Journal of Small Animal Practice (2009)
50, 180-185

→ Nº amostras por categoria agrupadas por local de origem/sede



→ Categoria 1 – Dx definitivo e específico

Specific diagnosis	Frequency
Lipoma	105
Mast cell tumour	49
Epidermal inclusion cyst	17
Lymphoid neoplasia	16
Histiocytoma	8
Sebaceous hyperplasia/adenoma	6
Perianal adenoma	5
Anal sac adenocarcinoma	4
Haemangiopericytoma	1
Hepatocellular carcinoma	1
Leishmaniasis	1
Melanoma	1
Multiple myeloma	1
Plasmacytoma	1
Thyroid adenoma (in a horse)	1
Transitional cell carcinoma	1
Total	218

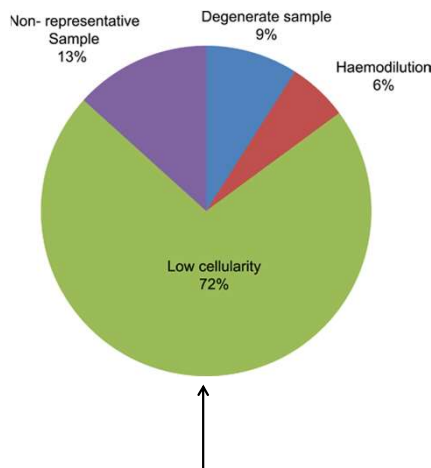


Utilização diagnóstica da Citologia (4)

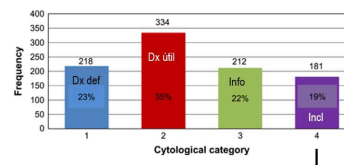
N. SKELDON AND E. DEWHURST

Journal of Small Animal Practice (2009)
50, 180-185

→ Razões para o exame ser inconclusivo



- Mais em amostras de gânglios linfáticos (30%)
- Amostras c/ ARTEFACTOS: rotura celular
- Amostras não REPRESENTATIVAS: gordura periganglionar, glândula salivar (submandibular)




The perceived and actual diagnostic utility of veterinary cytological samples

N. SKELDON AND E. DEWHURST

Journal of Small Animal Practice (2009)
50, 180-185

Specific diagnosis	Frequency
Lipoma	105
Mast cell tumour	49
Epidermal inclusion cyst	17
Lymphoid neoplasia	16
Histiocytoma	8
Sebaceous hyperplasia/adenoma	6
Perianal adenoma	5
Anal sac adenocarcinoma	4
Haemangiopericytoma	1
Hepatocellular carcinoma	1
Leishmaniasis	1
Melanoma	1
Multiple myeloma	1
Plasmacytoma	1
Thyroid adenoma (in a horse)	1
Transitional cell carcinoma	1
Total	218

Casos 1 a 4
≈ 85%



euvg

Obrigado

Ricardo Marcos

rmarcos@icbas.up.pt